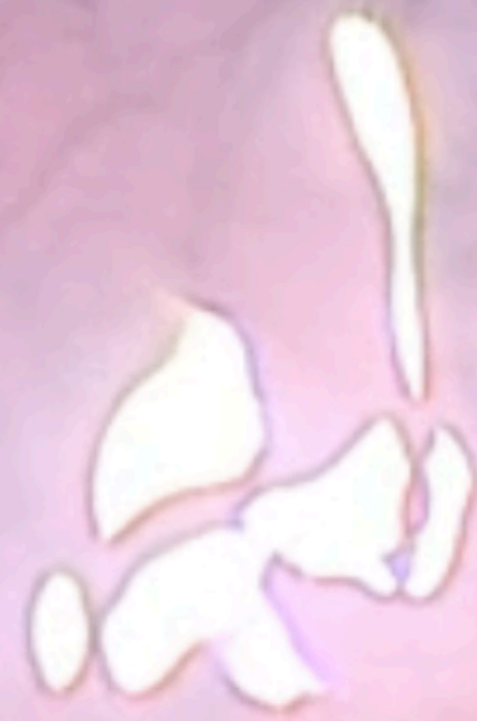


Beeran Meghpara, MD
Director of Refractive Surgery
Co-Chief of Cornea Service
Wills Eye Hospital



Cataract Surgery Through A Cloudy Cornea

New Orleans Academy of Ophthalmology
75th Annual Symposium

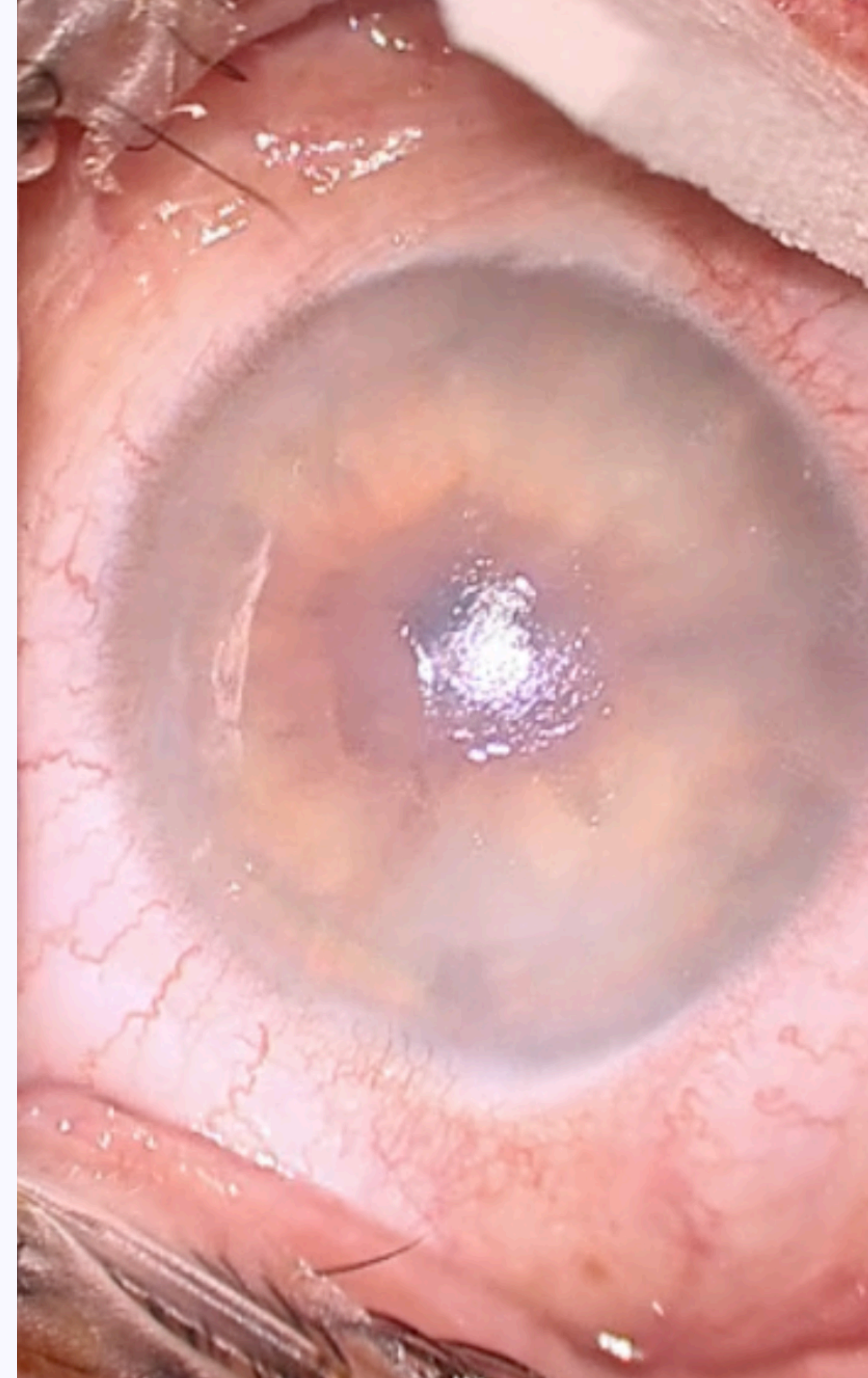

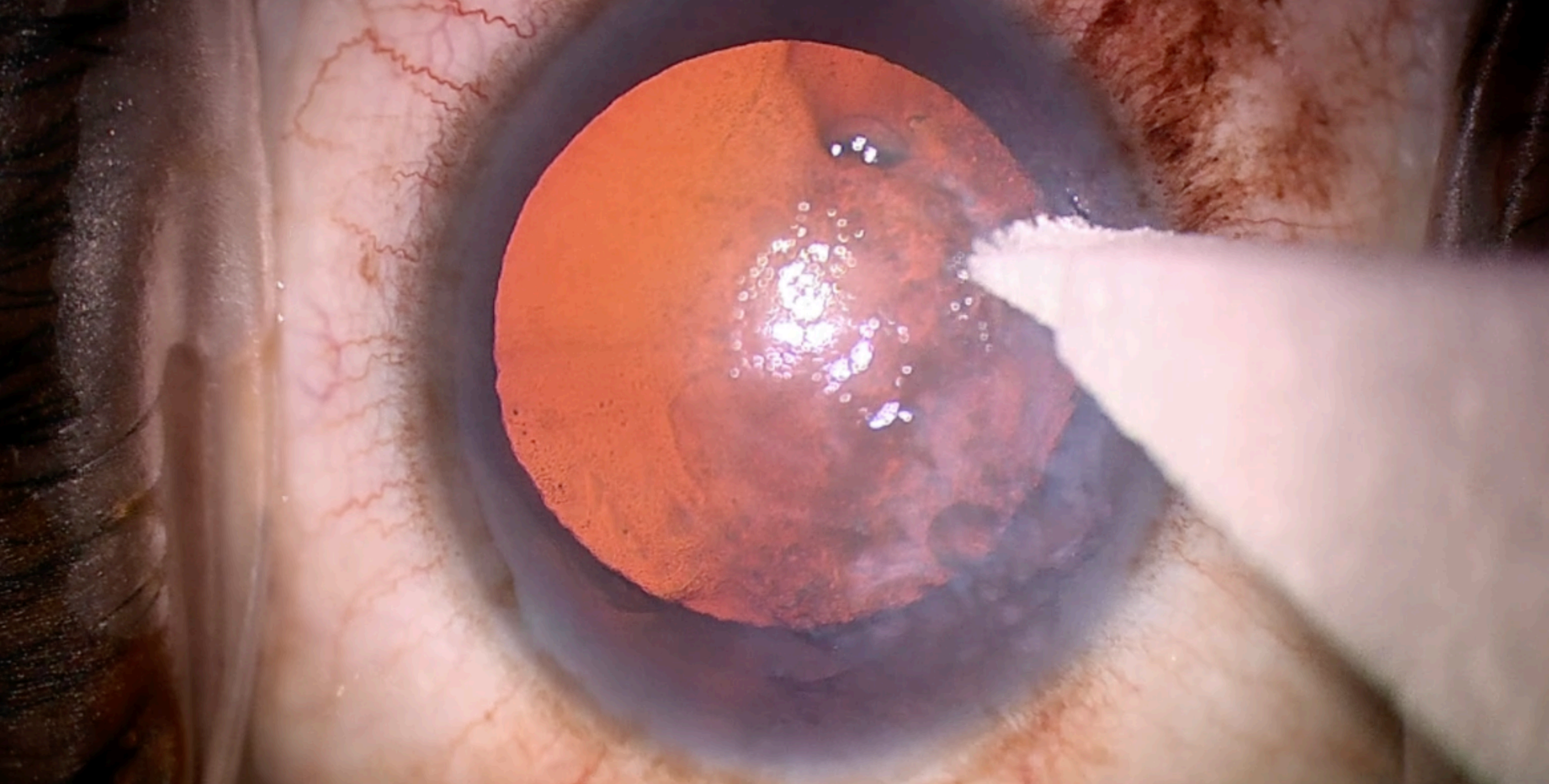
Clear It

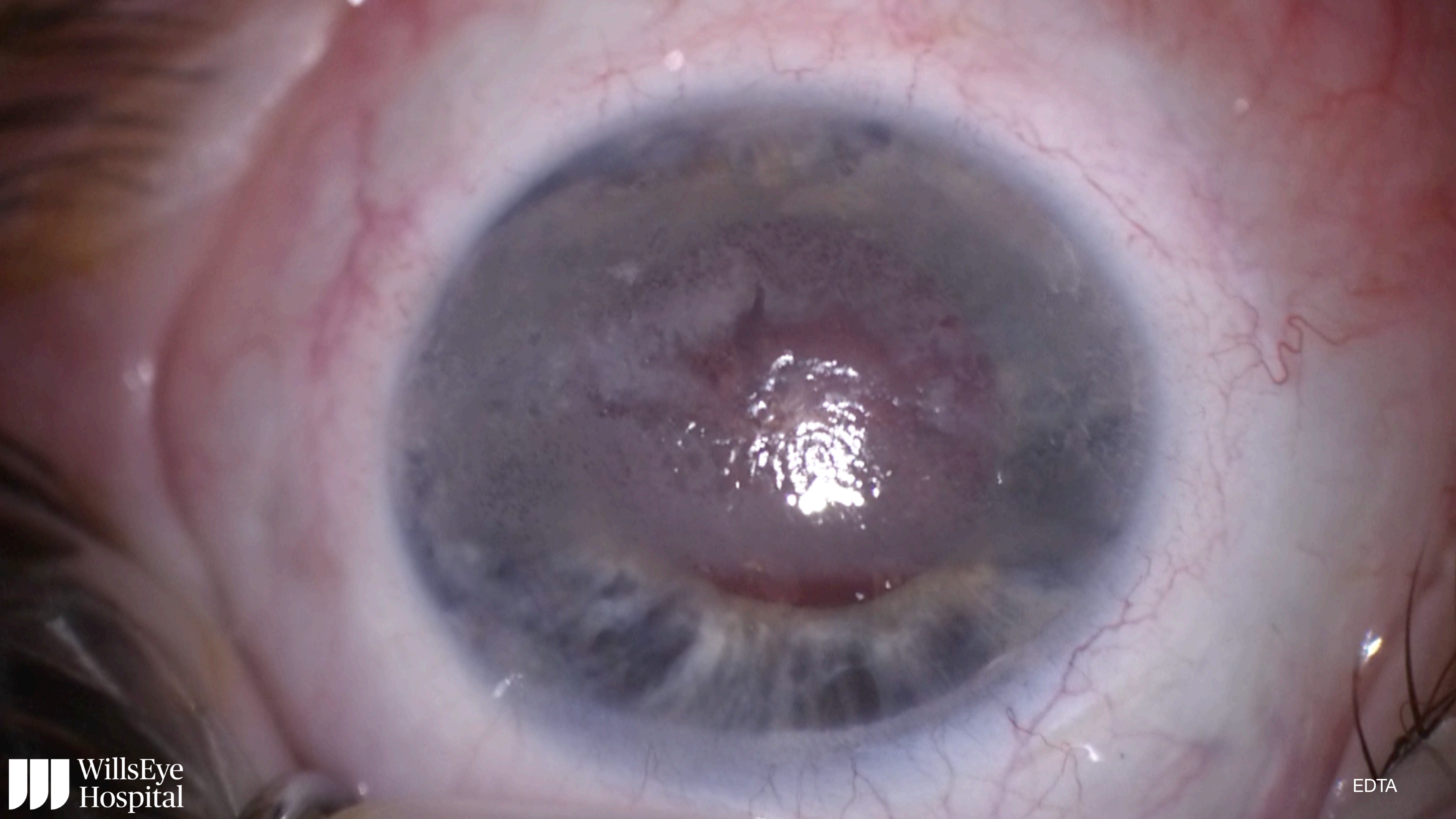Topical Options

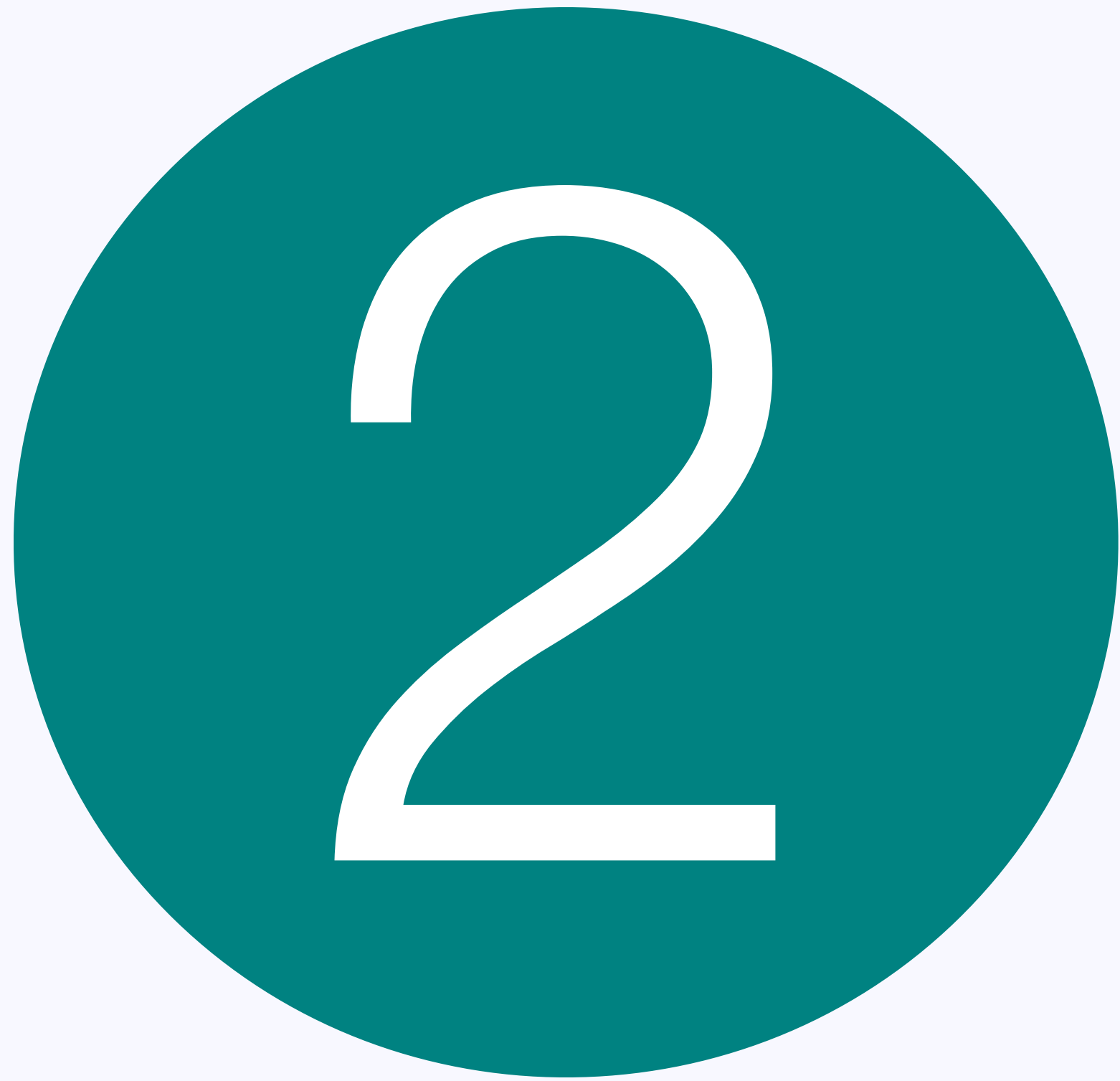Limited efficacy or availability

- 1 Sodium Chloride 0.5%
- 2 Hyperosmolar Viscoelastic
- 3 Glycerin

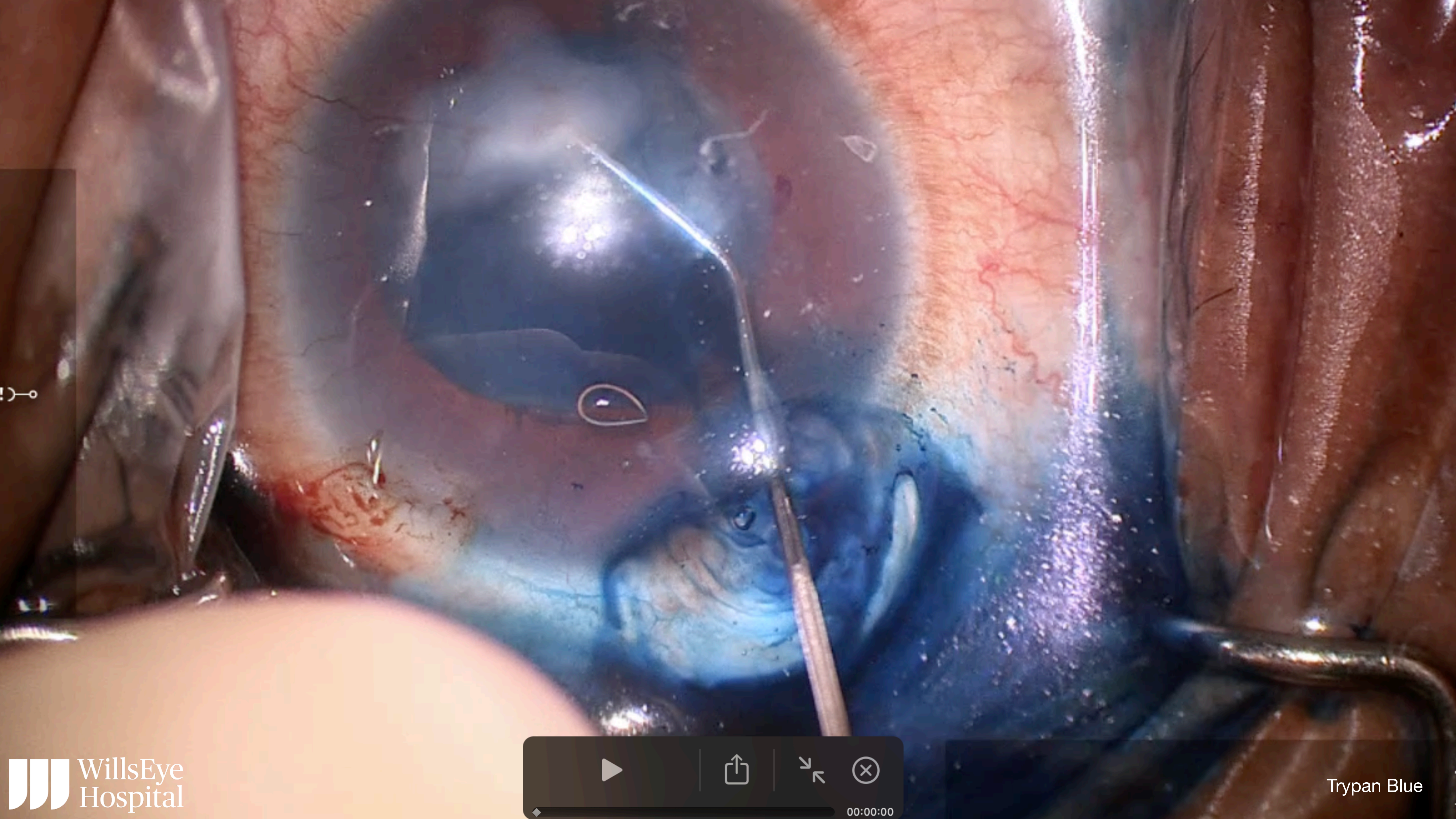

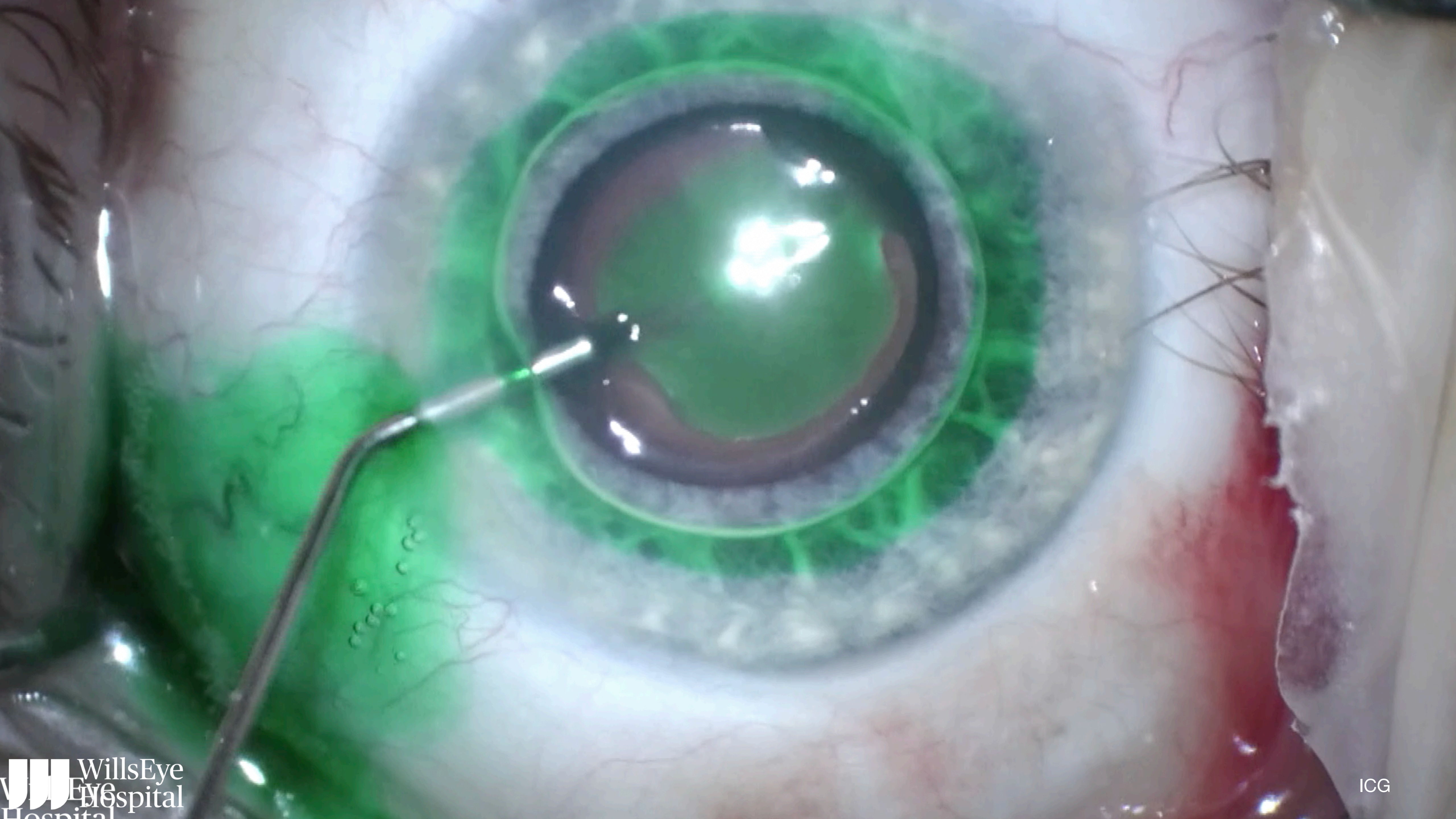






Optimize the View

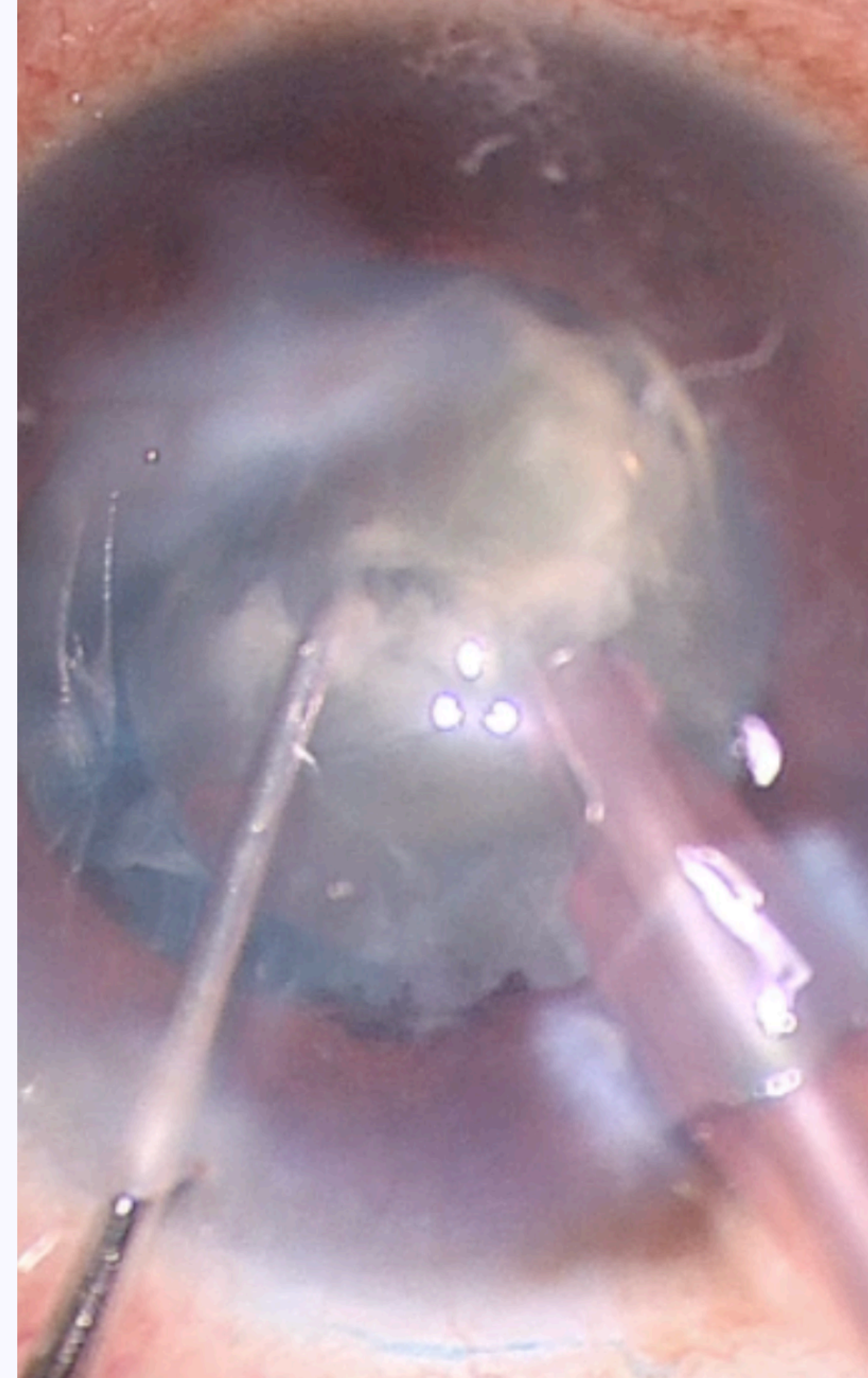


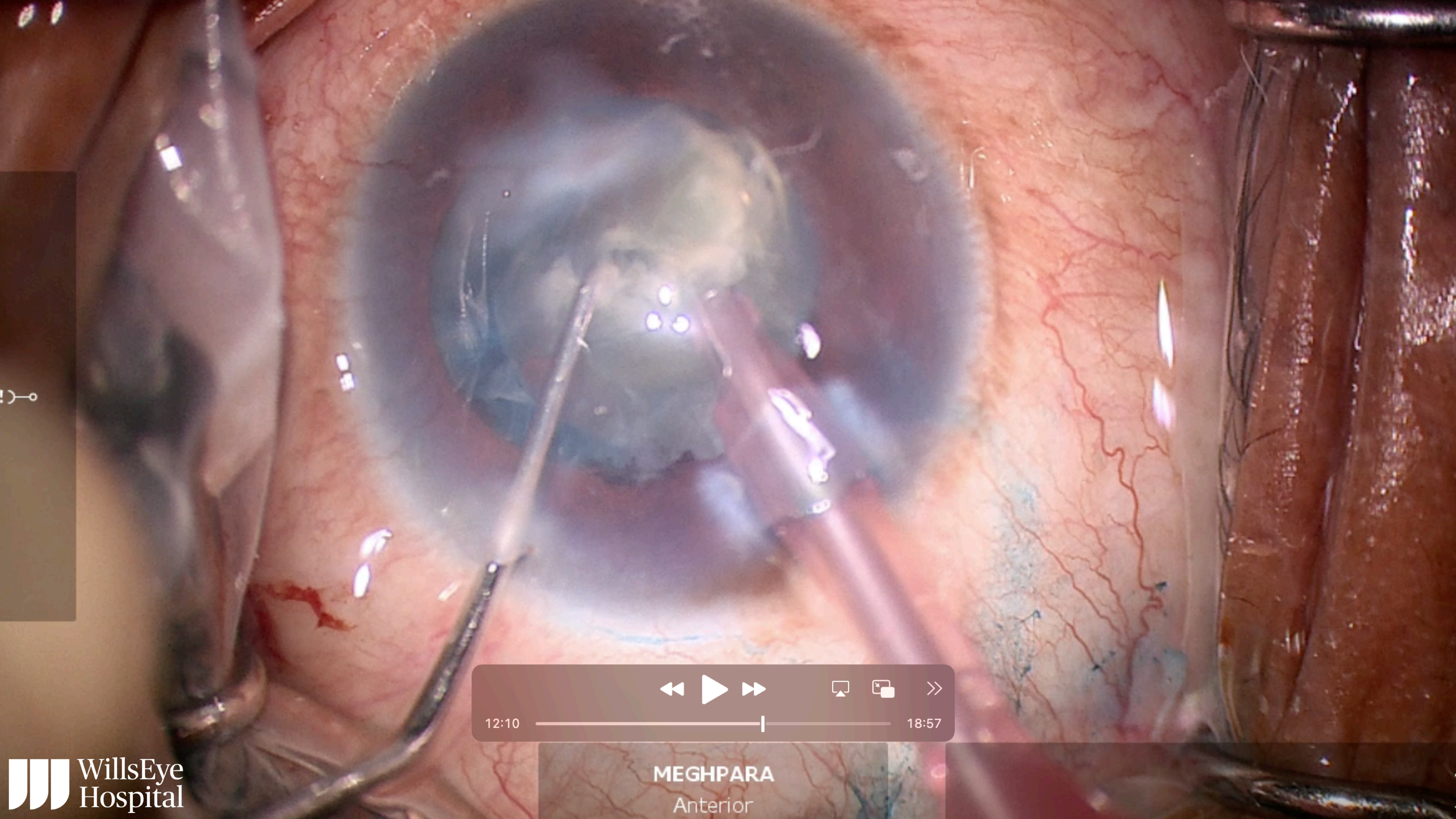

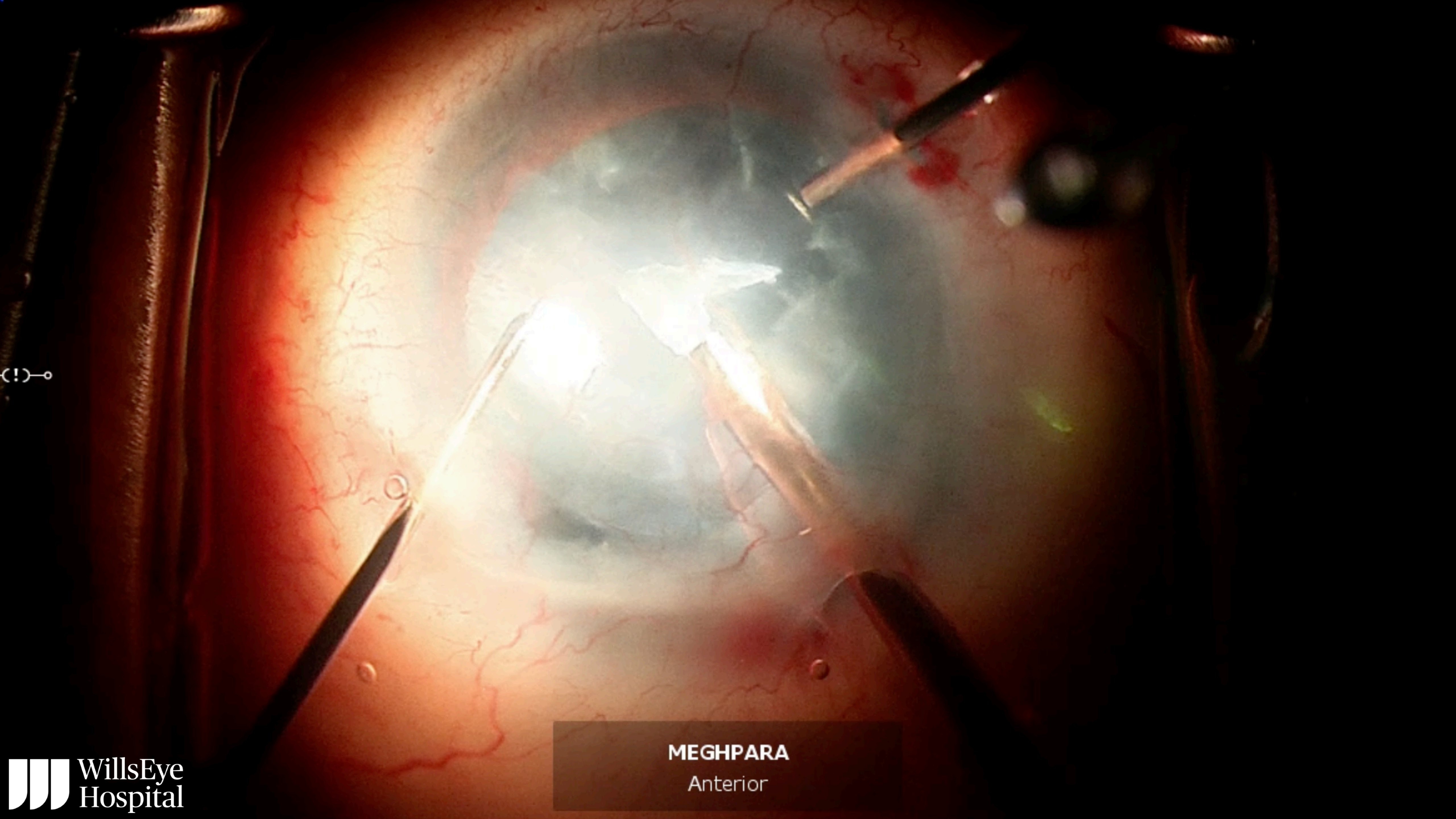
Intraoperative Maneuvers

Slow down and stay central

- Work in areas where cornea is clearest
- Tilt the eye to change angle of illumination
- Chopping techniques work best
- Tactile and audible cues



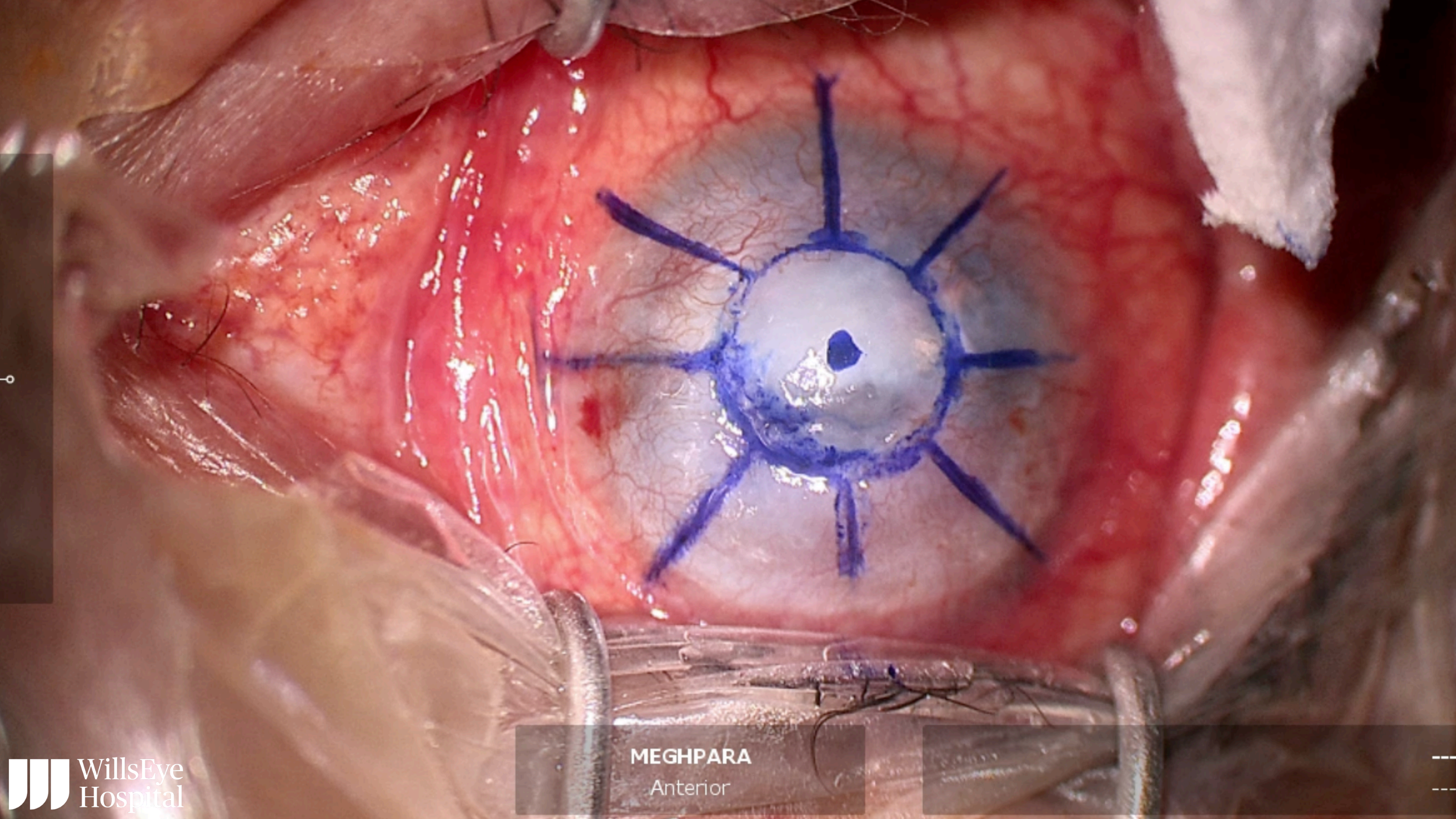




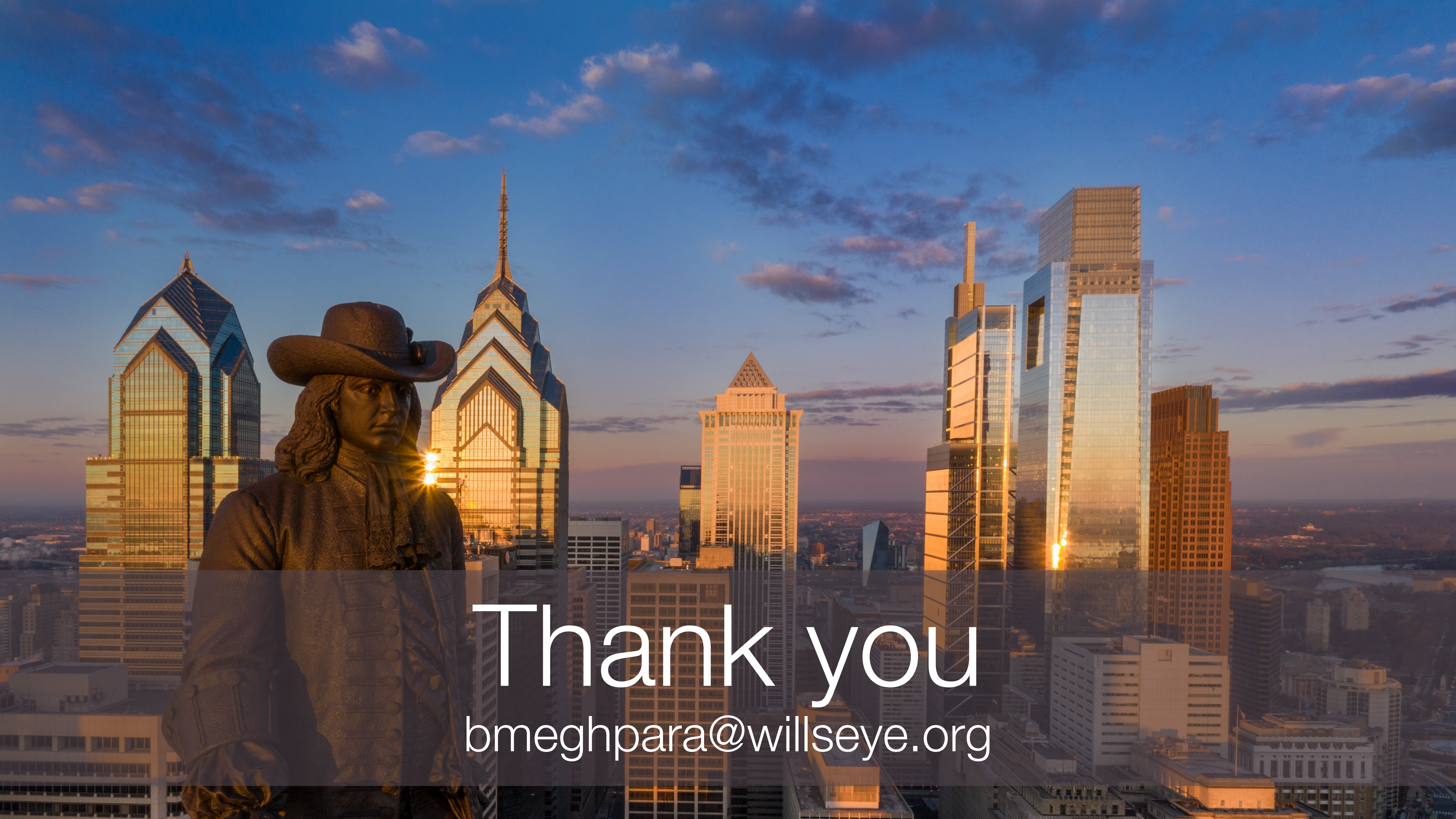(!)-o



Remove It



MEGHPARA
Anterior



Thank you
bmeghpara@willseye.org